

Single-Arm Evaluation of the AccuCirc Device for Early Infant Male Circumcision in Botswana

Rebeca M. Plank, MD, MPH,*†‡ Kathleen E. Wirth, ScD,‡§
 Nnamdi O. Ndubuka, MB, BS, Dip HIV Man (SA), MPH,|| Rasak Abdullahi, MD,‡
 Maggie Nkgau, RN,‡ Chiapo Lesetedi, MB, CHb, BAO(NUI), AFRCSI(RCSI),¶
 Kathleen M. Powis, MD, MPH,†‡# Mompoti Mmalane, MD,‡
 Joseph Makhema, MB, CHb, FRCP (UK),‡ Roger Shapiro, MD, MPH,†‡**
 and Shahin Lockman, MD, MSc*†‡

Abstract: Existing devices for early infant male circumcision (EIMC) have inherent limitations. We evaluated the newly developed AccuCirc device by circumcising 151 clinically well, full-term male infants with birth weight ≥ 2.5 kg within the first 10 days of life from a convenience sample in 2 hospitals in Botswana. No major adverse events were observed. There was 1 local infection, 5 cases of minor bleeding, and 1 case of moderate bleeding. In 3 cases, the device made only partial incisions that were completed immediately by the provider without complications. Parental satisfaction was high: $>96\%$ of mothers stated that they would circumcise a future son. The pre-assembled, sterile AccuCirc kit has the potential to overcome obstacles related to supply chain management and on-site instrument disinfection that can pose challenges in resource-limited settings. In our study, the AccuCirc was safe and it should be considered for programmatic EIMC in resource-limited settings.

Key Words: AccuCirc, early infant male circumcision, Botswana, neonatal, HIV, prevention

(*J Acquir Immune Defic Syndr* 2014;66:1–6)

BACKGROUND

Randomized trials have provided compelling evidence that male circumcision (MC) reduces men's risk of heterosexually acquired HIV-1 infection by about 60% ^{1–3} and it has been shown

to be a cost-saving intervention in sub-Saharan Africa.^{4,5} Although there have been no prospective randomized trials specifically demonstrating a protective effect of MC against HIV when done before adulthood, observational studies and models suggest that the cost–benefit and safety seem to be greatest when the procedure is performed in early infancy.^{6–9} The World Health Organization (WHO) recommends MC as a component of comprehensive HIV prevention programming and identifies neonatal circumcision as a low-risk procedure with fewer complications than circumcision performed at older ages. WHO recommends that “countries should consider how to promote neonatal circumcision in a safe, culturally acceptable and sustainable manner.”⁸

Specialized devices are required for safe early infant male circumcision (EIMC, performed ≤ 60 days of life¹⁰), and it is important to provide programs with options for devices that suit local needs so that this evidence-based HIV prevention strategy can be optimized and successfully implemented in routine public health settings. In 2010, WHO published the *Manual for Early Infant Male Circumcision under Local Anaesthesia*,¹⁰ which included the Mogen, Gomco, and Plastibell devices. At the time of publication, the AccuCirc was a new EIMC device (approved by the US Food and Drug Administration in 2007) and it had not yet undergone field evaluation to assess its performance in resource-limited settings.

Although published reports and our own studies have shown a very low rate of serious adverse events associated with EIMC,^{11–15} we believe that the adverse event rate could be decreased. There are rare but serious potential complications associated with all 3 devices currently on the WHO prequalified list of EIMC devices: (1) use of the Mogen clamp can result in partial or total amputation of the glans penis or removal of too little foreskin^{10,13,16–18}, (2) migration of the Plastibell can result in necrosis of the glans and other injuries, and risk is increased if the incorrect size “bell” is utilized,^{10,14,19,20} and (3) mismatching the sizes of the separate pieces of the Gomco clamp can result in laceration of the glans penis.^{10,16} Sequelae of these rare adverse outcomes may be worse in settings with limited resources for treating such complications.

The potential complications of these 3 devices are inherent in their design. Although training and increased experience of the providers can reduce the risk of complications, the design of the devices themselves will always present the

Received for publication November 18, 2013; accepted January 24, 2014.

From the *Division of Infectious Diseases, Department of Medicine, Brigham and Women's Hospital, Boston, MA; †Department of Immunology and Infectious Diseases, Harvard School of Public Health, Boston, MA; ‡Botswana-Harvard School of Public Health AIDS Initiative Partnership for HIV Research and Education, Gaborone, Botswana; §Department of Epidemiology, Harvard School of Public Health, Boston, MA; ||Northern Inter-Tribal Health Authority, Prince Albert, Saskatchewan, Canada; ¶Botswana Ministry of Health, Gaborone, Botswana; #Departments of Internal Medicine and Pediatrics, Massachusetts General Hospital, Boston, MA; and; **Division of Infectious Diseases, Beth Israel Deaconess Medical Center, Boston, MA.

Supported by Grant U2GSP000941; the National Institute of Health Grant K23 AI084579.

The authors have no conflicts of interest to disclose.

Correspondence to: Rebeca M. Plank, MD, MPH, Division of Infectious Diseases, Brigham and Women's Hospital, Department of Medicine, 15 Francis Street, PBB-A-4, Boston, MA 02115 (e-mail: rplank@partners.org).
 Copyright © 2014 by Lippincott Williams & Wilkins

potential for adverse events. The AccuCirc has several safety features that make an adverse event resulting from the device itself extremely unlikely. It is a 1-time use device that has a built-in shield to protect the glans from laceration and it incorporates a retractable blade that cannot be reused. We therefore conducted a single-arm field evaluation of the AccuCirc device in Botswana to assess safety and parental satisfaction.

METHODS

Informed Consent, Safety Monitoring, and Role of the Funding Source

Written informed consent was obtained from the mothers or legal guardians (if mothers were age <21 years, the age of majority in Botswana) before neonates were enrolled. The single-arm study was approved by the Botswana Ministry of Health's Health Research and Development Committee and by Brigham and Women's Hospital Institutional Review Board. An independent Data Safety Monitoring Committee was responsible for safety monitoring. This trial is registered with ClinicalTrials.gov with the number NCT00971958. The sponsors of the study had no role in study design, data collection, data analysis, data interpretation, or writing of the report. The corresponding author had full access to all the data in the study and had final responsibility for the decision to submit for publication. The AccuCirc devices used in this evaluation were donated by Clinical Innovations, Murray, UT.

Subjects

Mothers and infants were enrolled between February and September 2011 at 2 hospitals in southeastern Botswana: 1 in the capital city, Gaborone, and 1 in the village of Molepolole. A convenience sample of eligible mothers and infants was identified and recruited by study staff in maternity wards in the respective hospitals. Maternal eligibility criteria were Botswana citizenship, nonincarceration, and ability to follow-up at 7 days and 6 weeks after the procedure. Infant eligibility criteria were male gender, gestational age ≥ 37 weeks, age ≤ 10 days of life, birth weight ≥ 2500 g, no evidence of neonatal sepsis or other illness requiring hospitalization, no family history of bleeding disorder, and no genital or other abnormality that is a contraindication to EIMC. The maternal HIV status was not one of the inclusion/exclusion criteria and thus was not recorded for the purposes of this study.

AccuCirc Device, Kit, and Procedure

The AccuCirc comes in a sterile pack that contains the device itself, a surgical pen, drape, 2 hemostats, 3 betadine swabs, xeroform dressing, gauze, and cleansing wipe, and all items are disposable. The device itself consists of (1) a flexible foreskin probe and shielding ring and (2) a single-action clamp that contains a circular blade. It is available in 2 sizes: 1.1 and 1.3 cm (penile diameter). Complete manufacturer instructions are available online.²¹ A surgical pen mark is made on the foreskin at the level of the corona. The physiologic adhesions between the foreskin and the glans are removed using the flexible foreskin

probe. With the use of hemostats, the shielding ring is then inserted into the preputial space, between the foreskin and the glans. The adjustable foreskin holder is deployed, and using a hemostat, the tissue is aligned according to the pen mark within the inner and outer rings. The clamp is applied and activated to deliver a circumferential, hemostatic crush while simultaneously incising the foreskin. After 5 minutes of hemostatic pressure, the clamp is released and the wound is dressed (Fig. 1).

Study Intervention

All circumcisions were performed by a study physician (N.N., R.A., or R.P.) using clean techniques (sterile kit and new, nonsterile gloves, in a clean clinical setting but not a surgical theater).^{12,22} The study physicians, who had no significant previous experience in performing EIMC with the AccuCirc device, were trained by an AccuCirc-experienced physician before study initiation and only performed procedures independently after competency was demonstrated.

Study staff performed a physical examination to exclude infants with abnormalities precluding circumcision. Infants had approximately 1 g of eutectic mixture of local anesthetic (EMLA) applied to the outer foreskin and shaft of the penis and covered with an occlusive dressing (the pros and cons of various local anesthetics approved for use for EIMC have been previously described²³ (it should be noted that EMLA should not be used on the mucosal/inner surface of the foreskin because of higher absorption, possibly leading to systemic toxicity); EMLA was wiped off before the procedure. During the procedure, infants were given concentrated sucrose solution either by gloved finger or by syringe to augment the anesthetic effect of EMLA, as has been previously described.²⁴⁻²⁶ Infants' upper bodies and arms were swaddled, and legs were restrained by an assistant. Infants had the genital area, lower abdomen, and upper legs cleansed with betadine immediately before EIMC.

After circumcision, infants were checked for postprocedure bleeding or other immediate complications. Mothers were asked to wait with the infant for 2 hours following the procedure before leaving the facility to ensure there was no excessive bleeding and to ensure that the infant had urinated. Mothers were given Vaseline for wound care and written postprocedure care instructions that included a phone number to reach a study physician 24 hours a day, 7 days a week, in case of any questions or concerns.

Follow-up and Evaluation

Postprocedure follow-up visits were scheduled at 7 days and 6 weeks. At these visits, parents were asked about complications and child outpatient medical cards were also reviewed for evidence of visits to nonstudy clinics or providers for adverse events potentially related to the procedure. The infants also had a physical examination, including inspection of the circumcision site, by 1 of the 3 study physicians.

Outcomes

The primary study outcomes were adverse events and parental satisfaction. We also measured the time taken to

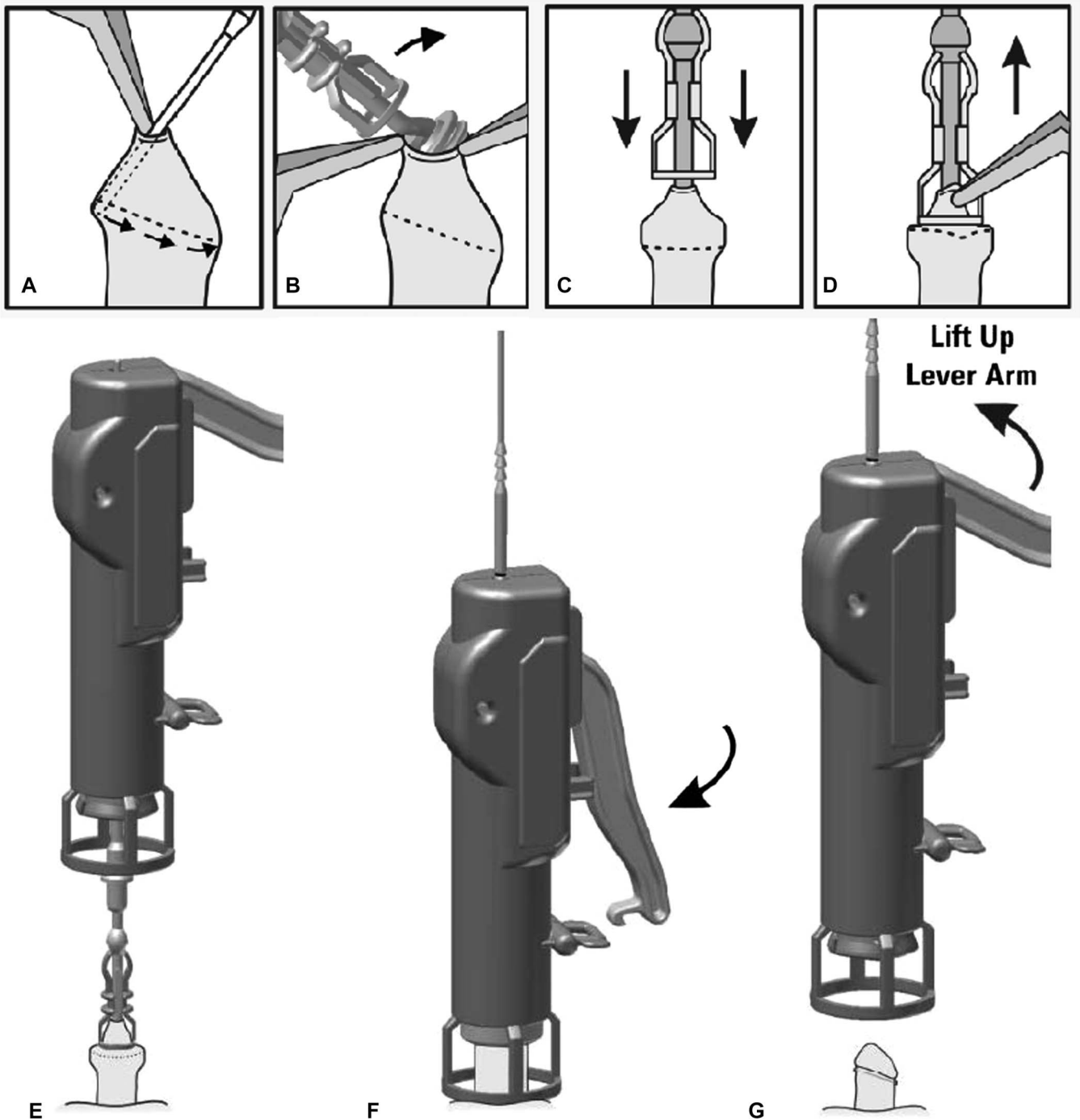


FIGURE 1. A, A surgical pen mark (indicated by dotted line) is made on the foreskin at the level of the corona. Physiologic adhesions are removed using the flexible foreskin probe. B, With the use of hemostats, the shielding ring is then inserted into the preputial space, between the foreskin and the glans. C, The adjustable foreskin holder is deployed, and (D) using a hemostat, the tissue is aligned according to the pen mark within the inner and outer rings. E, The clamp is applied and (F) activated to deliver a circumferential, hemostatic crush while simultaneously incising the foreskin. G, After 5 minutes of pressure, the clamp is released and the wound is dressed.

perform the procedure from the infant’s diaper being removed until the time it was replaced and recorded the number of AccuCirc devices opened so that correct sizing was achieved.

Adverse events that were potentially related to EIMC were defined before study initiation and categorized as bleeding, infection, structural, and other. Minor adverse events included bleeding, requiring only the application of

pressure beyond the immediate postprocedure period or infection limited to the circumcision site. Moderate adverse events included intervention for bleeding other than pressure (eg, suturing) or soft-tissue infection spreading beyond the penis (lower abdominal wall, upper legs). Major adverse events included the need for a separate clinic visit or hospitalization for bleeding from the circumcision site; need for intravenous fluids or blood products; systemic infection/sepsis; removal of too much or incorrect tissue; removal of too little tissue requiring repeat procedure; structural injury to the glans, urethra, or shaft; or subsequent problems with urination.

To assess parental satisfaction, we used a structured questionnaire that was administered at the 6-week follow-up visit. "Highly or completely" was defined as a score of 90% or greater on a visual analogue scale from 0% to 100%. Parents were also asked if they would be likely to choose EIMC for a future son.

Sample Size

This was a pilot study aiming to explore the performance of the AccuCirc in resource-limited settings. This study was not powered to detect a statistically significant difference in major adverse events when comparing the AccuCirc with other devices (previously reported rates of major complications following EIMC are as low as 0.2% in well-resourced settings).^{11,12,15}

Statistical Analysis

Frequency tables for each of the primary outcomes present proportions, means, medians, SDs, and interquartile ranges (IQRs) as appropriate. All statistical analyses were performed with SAS software version 9.3 (SAS Institute, Cary, NC).

RESULTS

Study Participants

We circumcised 151 infants at a median age of 2 days (IQR: 2–4 days) and a median birth weight of 3.13 kg (IQR: 2.95–3.42 kg). On average, study participants were born at an estimated gestational age of 39.4 weeks. Three additional infants were enrolled, but did not undergo circumcision: 2 experienced a local reaction to the topical anesthesia we previously described,²³ which precluded continuing with the procedure, and 1 was found, after the foreskin was retracted but before circumcision, to have glanular hypospadias, which made him ineligible for the procedure. We opened 155 kits, and 4 infants required a different size: ultimately we used 117 size 1.1-cm clamps and 34 size 1.3 cm clamps. The average time required to complete a single procedure was 16.5 minutes (SD: 6.7 minutes).

Of the 151 infants circumcised, 150 completed the 7-day follow-up visit; 1 child did not return in person for any follow-up, but his parents were contacted by telephone and reported no adverse events or complications from the procedure. One hundred thirty seven infants returned for the 6-week follow-up visit.

Adverse Events

We observed 10 adverse events (6.6%), all of which were classified as either minor ($n = 9$) or moderate ($n = 1$) (Table 1). Five cases of minor bleeding occurred (all resolved with brief, local pressure). One case of local infection was diagnosed by a non-study physician and not confirmed by the study team; the infant was prescribed oral amoxicillin and had no further sequelae. In 3 cases, the AccuCirc device made only a partial incision (cut approximately 70% of circumference) requiring manual completion by the study physician. In these 3 instances, the EIMC was completed as a single procedure: immediately upon realizing that the cut was incomplete, the provider used sterile surgical scissors to incise along the hemostatic crush-line made by the AccuCirc device without further complications. The only moderate adverse event involved prolonged bleeding (90 minutes) immediately following the procedure in an infant who had inadvertently not received Botswana standard of care, prophylactic vitamin K at birth. Bleeding resolved approximately 30 minutes after administration of 2 mg of phytomenadione (vitamin K1) intramuscularly. A complete case report describing the event has been previously published.²⁷

Parental Satisfaction

Of the 137 infants who returned for the 6-week follow-up visit, 91% of mothers reported being highly or completely satisfied with the procedure; 97% stated they would highly or completely recommend the procedure to a friend or relative. More than 96% stated that they would circumcise another son should they have one in the future (Table 1).

DISCUSSION

In this single-arm field evaluation of the AccuCirc device for EIMC in Botswana, we observed no major

TABLE 1. Adverse Events and Parental* Satisfaction Following EIMC Among $N = 151$ Infants Circumcised With the AccuCirc Device From February to September 2011 in Southeastern Botswana

Outcome (Total n With Data)	N (%)
Adverse events ($n = 151$)	
Bleeding	6 (4.0)
Mild	5 (3.3)
Moderate	1 (0.7)
Severe	0 (0.0)
Local infection†	1 (0.7)
Structural	0 (0.0)
Other (incomplete incision)‡	3 (2.0)
Parental* satisfaction at 6 weeks	
Completely or highly satisfied with procedure ($n = 137$)	125 (91.2)
Would recommend highly or completely EIMC ($n = 133$)	127 (95.5)
Would circumcise another son in the future (Y/N) ($n = 137$)	132 (96.4)

*Only mothers (no fathers) responding.

†Not confirmed by study team; treated with oral antibiotics.

‡Device made only a partial incision requiring manual completion by the provider.

complications. Minor bleeding (3.3%), which is expected in any surgical procedure, was similar to our previous study of EIMC using the Mogen clamp (3.2%).¹⁴ Although 13 children were not seen for their second scheduled follow-up visit, they were seen by study staff for their first visit. Although complications from EIMC are rare, many will occur immediately following (bleeding, soft-tissue injury) or within a few days of the procedure (infection), and in evaluating the safety of the AccuCirc, these complications were our main focus. Long-term follow-up of issues such as unsatisfactory cosmetic result or meatal stenosis (that may be independent of which device is used for EIMC) are beyond the scope of this pilot study but do deserve systematic investigation. Because serious adverse events are very rare after the immediate post-EIMC period, parental education as to what should prompt need for follow-up (further bleeding, any fever, abnormal discoloration or malodor of wound) should ensure optimal care. In our study design, mothers were asked to wait with the infant for 2 hours following the procedure to ensure there was no excessive bleeding and to ensure that the infant had urinated. Mothers were provided with written instructions along with a phone number, operational 24 hours per day and 7 days per week, for the staff physicians in case of participant questions or concerns. This may be a model that could be replicated for scale-up of EIMC programs. Parental satisfaction with the procedure was high and >96% of parents reported being very likely or likely to circumcise another son in the future.

Although the device failed to completely incise the circumference of the foreskin in 3 instances, no harm resulted to the infants. As the applied pressure is determined by the device mechanics and not by the clinician deploying it, the device may need revision if this is found to occur in larger studies. Alternatively, it could be that the clinician must make sure that the foreskin is evenly distributed along the foreskin holder before deploying the blade so as to ensure an even incision. The potential for incomplete incisions would limit the use of the device to facilities where standard surgical instruments, such as scissors, would be readily available until the issue has been fully resolved.

Ideal device characteristics for scale-up of EIMC programs differ from those needed in adult MC programs. The 60-day age limit for EIMC is based on safety data.¹⁰ As babies get older and heavier, they are more likely to bleed following the procedure and this could negate the sutureless nature of the procedure. Because of the limited window in which the procedure can be performed, the procedure needs to be offered in a sustained fashion (rather than as a mass campaign) and near to where infants are born or receive health care (rather than recruiting men from a large catchment area to come to a central location where dozens of procedures can be done per day). EIMC programs therefore require device characteristics suited to rural maternity clinics or home-based service provision, where procedures will likely be performed by nonphysicians and where moderate or major complications must be minimized. Our findings suggest that the safety characteristics of the AccuCirc device may be well suited for EIMC.

The AccuCirc device could also simplify supply chain management and eliminate the need for reusable instrument

inventory and sterilization at remote sites because it comes in a sterile pack containing necessary supplies together with the device.²⁸ In contrast, use of the Plastibell places an additional burden on supply chain management because all 6 sizes must be continually stocked, and use of the Mogen and Gomco clamps require reliable and timely instrument disinfection processes.

We would like to emphasize that the most important criteria as EIMC is operationalized is that the infant must be clinically well before undergoing the procedure. Unfortunately, neonatal mortality continues to be unacceptably high in many parts of the world and although the EIMC procedure itself is not likely to result in major morbidity or mortality, it is important that such events not be erroneously ascribed to EIMC as the procedure is scaled up. We believe that each program will have to contextually customize inclusion criteria, although being clinically well should always be a criterion. Context-specific programmatic determinations will have to be made regarding timing of EIMC for those infants who fail to meet programmatic inclusion criteria at birth (eg, ill infants, low birth weight, prematurity).

In summary, we safely and acceptably circumcised 151 infants in Botswana with the AccuCirc device. If additional field studies confirm our findings,²⁹ the AccuCirc should be considered for WHO prequalification to increase options for safe and sustainable scale-up of EIMC in resource-limited settings.

REFERENCES

1. Auvvert B, Taljaard D, Lagarde E, et al. Randomized, controlled intervention trial of male circumcision for reduction of HIV infection risk: the ANRS 1265 Trial. *PLoS Med.* 2005;2:e298.
2. Bailey RC, Moses S, Parker CB, et al. Male circumcision for HIV prevention in young men in Kisumu, Kenya: a randomised controlled trial. *Lancet.* 2007;369:643–656.
3. Gray RH, Kigozi G, Serwadda D, et al. Male circumcision for HIV prevention in men in Rakai, Uganda: a randomised trial. *Lancet.* 2007; 369:657–666.
4. White RG, Glynn JR, Orroth KK, et al. Male circumcision for HIV prevention in sub-Saharan Africa: who, what and when? *AIDS.* 2008; 22:1841–1850.
5. Njeuhmeli E, Forsythe S, Reed J, et al. Voluntary medical male circumcision: modeling the impact and cost of expanding male circumcision for HIV prevention in eastern and southern Africa. *PLoS Med.* 2011;8: e1001132.
6. Binagwaho A, Pegurri E, Muita J, et al. Male circumcision at different ages in Rwanda: a cost-effectiveness study. *PLoS Med.* 2010;7:e1000211.
7. Weiss HA, Larke N, Halperin D, et al. Complications of circumcision in male neonates, infants and children: a systematic review. *BMC Urol.* 2010;10:2.
8. WHO. New data on male circumcision and HIV prevention: policy and programme implications. 2007. Available at: http://www.who.int/hiv/mediacentre/MCRecommendations_en.pdf. Accessed March 12, 2014.
9. UNAIDS. *Neonatal and Child Male Circumcision: A Global Review.* Geneva, Switzerland: UNAIDS; 2010.
10. WHO. *Manual for Early Infant Male Circumcision Under Local Anaesthesia.* Geneva, Switzerland: WHO Document Production Services; 2011.
11. Wiswell TE, Geschke DW. Risks from circumcision during the first month of life compared with those for uncircumcised boys. *Pediatrics.* 1989;83:1011–1015.
12. Ben Chaim J, Livne PM, Binyamini J, et al. Complications of circumcision in Israel: a one year multicenter survey. *Isr Med Assoc J.* 2005;7: 368–370.
13. Young MR, Bailey RC, Odoyo-June E, et al. Safety of over twelve hundred infant male circumcisions using the Mogen clamp in Kenya. *PLoS One.* 2012;7:e47395.

14. Plank RM, Ndubuka NO, Wirth KE, et al. A randomized trial of mogen clamp versus plastibell for neonatal male circumcision in Botswana. *J Acquir Immune Defic Syndr*. 2013;62:e131–137.
15. Christakis DA, Harvey E, Zerr DM, et al. A trade-off analysis of routine newborn circumcision. *Pediatrics*. 2000;105:246–249.
16. USFDA. *Potential for Injury From Circumcision Clamps*. Silver Spring, MD: United States Food and Drug Administration; 2000.
17. Sherman J, Borer JG, Horowitz M, et al. Circumcision: successful glanular reconstruction and survival following traumatic amputation. *J Urol*. 1996;156:842–844.
18. Patel HI, Moriarty KP, Brisson PA, et al. Genitourinary injuries in the newborn. *J Pediatr Surg*. 2001;36:235–239.
19. Bode CO, Ikhisemogie S, Ademuyiwa AO. Penile injuries from proximal migration of the Plastibell circumcision ring. *J Pediatr Urol*. 2010;6:23–27.
20. Gee WF, Ansell JS. Neonatal circumcision: a ten-year overview: with comparison of the Gomco clamp and the Plastibell device. *Pediatrics*. 1976;58:824–827.
21. Clinical Innovations. *AccuCirc Single Action Circumcision Device: Instructions for Use*. Murray, UT: Clinical Innovations; 2010. Available at: http://www.clinicalinnovations.com/site_files/files/AccuCirc_IFUs.pdf. Accessed March 12, 2014.
22. Naimer SA, Trattner A. Are sterile conditions essential for all forms of cutaneous surgery? The case of ritual neonatal circumcision. *J Cutan Med Surg*. 2000;4:177–180.
23. Plank RM, Kubiak DW, Abdullahi RB, et al. Loss of anatomical landmarks with eutectic mixture of local anesthetic cream for neonatal male circumcision. *J Pediatr Urol*. 2013;9:e86–e90.
24. Taddio A. Pain management for neonatal circumcision. *Paediatr Drugs*. 2001;3:101–111.
25. Brady-Fryer B, Wiebe N, Lander JA. Pain relief for neonatal circumcision. *Cochrane Database Syst Rev*. 2004;(4):CD004217.
26. Blass EM, Hoffmeyer LB. Sucrose as an analgesic for newborn infants. *Pediatrics*. 1991;87:215–218.
27. Plank RM, Steinmetz T, Sokal DC, et al. Vitamin K deficiency bleeding and early infant male circumcision in Africa. *Obstet Gynecol*. 2013;122:503–505.
28. Arasaratnam A, Humphreys G. Emerging economies drive frugal innovation. *Bull World Health Organ*. 2013;91:6–7.
29. WHO. Overview of the Prequalification of Male Circumcision Devices Assessment Process. 2011. Available at: http://www.who.int/diagnostics_laboratory/evaluations/111216_pqmc_007_overview_document.pdf?ua=1. Accessed March 12, 2014.