

Diagnosing Rupture of Membranes Using Combination Monoclonal/Polyclonal Immunologic Protein Detection

Tovah Thomasino, D.O., Carol Levi, M.D., Michael Draper, M.D., and A. George Neubert, M.D.

OBJECTIVE: To compare the accuracy of a new combination monoclonal/polyclonal immunoassay point-of-care test with that of current conventional clinical assessment for diagnosis of ruptured amniotic membranes.

STUDY DESIGN: This was a multicenter prospective observational study performed in patients presenting with signs or symptoms of ruptured amniotic membranes. This clinical trial included 3 sites in the United States. Initial evaluation included both the standard clinical assessment for rupture of membranes (ROM) (speculum examination for fluid pooling, ferning, and nitrazine test), as well as the use of a new combination immunoassay test containing a combination monoclonal/polyclonal antibody approach to detect placental protein 12 (PP12) and α -fetoprotein (AFP). ROM was diagnosed if fluid was seen leaking from the cervical os, or if 2 of the 3 conditions were present: pooling of fluid, positive nitrazine test, or ferning.

ROM was confirmed on review of the medical records following delivery.

RESULTS: Of the 285 patients (15–42 weeks of gestation), the false positive rate for the new combination immunoassay test was 9% and the false negative rate was 0.5%, sensitivity 99%, specificity 91%, positive and negative predictive values of 95% and 99%, respectively. The conventional clinical evaluation's sensitivity was

...perhaps the value of immunoassay protein tests are to alert the physician of the presence of these proteins in the vaginal secretions...

85%, specificity 98%, with positive and negative predictive values of 99% and 77%. Ferning's sensitivity was 99%, specificity 72%, with positive and negative predictive values of 80% and 99%. Nitrazine testing's sensitivity was 93%, specificity 83%, with positive and negative predictive values of 90% and 88%.

CONCLUSION: This combination monoclonal and polyclonal immunoassay test that detects PP12 and AFP has an efficacy comparable to conventional testing and better than the individual components of conventional

From the Departments of Obstetrics and Gynecology, Swedish Covenant Hospital, Chicago, Illinois; University of Utah Medical Center, Salt Lake City, Utah; and The Reading Hospital and Medical Center, Reading, Pennsylvania.

A subset of this data was presented in abstract form at the 59th Annual American Congress of Obstetricians and Gynecologists Clinical Meeting, Washington, D.C., April 30–May 4, 2011.

Clinical Innovations, LLC, Murray, Utah, provided the ROM Plus kits.

Address correspondence to: Carol Levi, M.D., or Tovah Thomasino, D.O., Department of Obstetrics and Gynecology, Swedish Covenant Hospital, 5145 North California Avenue, Chicago, IL 60625 (clevi@schosp.org).

Financial Disclosure: The authors have no connection to any companies or products mentioned in this article.

testing (ferning, nitrazine), is a quick and easy-to-use test that can be performed by a wider variety of care providers, and can improve triage and management of patients suspected of ROM. (J Reprod Med 2013;58: 187–194)

Keywords: antibodies, immunoassay, premature rupture of fetal membranes, PROM (pregnancy), rupture of membranes.

Premature rupture of membranes (PROM) is defined as spontaneous rupture of the fetal membranes prior to the onset of labor.¹ PROM is one of the most common diagnostic dilemmas in contemporary obstetrical practice, affecting 5–10% of all pregnancies. Preterm PROM (PPROM), defined as PROM prior to 37 weeks' gestation, is responsible for 20–40% of preterm births.² Early and accurate diagnosis of PROM would allow for specific interventions necessary to optimize perinatal outcome and minimize serious complications, including preterm delivery and infections such as chorioamnionitis and neonatal sepsis.^{3,4} Conversely, a false-positive diagnosis of PROM may lead to overtreatment with obstetric interventions including hospitalization, administration of medications (antibiotics and corticosteroids), and even iatrogenic premature delivery in some cases. Hence accurate and timely diagnosis of PROM is of critical importance to clinicians.^{5,6}

The conventional clinical evaluation for the diagnosis of rupture of membranes (ROM), the sterile speculum examination, is frequently inaccurate.^{7,8} This is often due to high false-positive rates in nitrazine testing as a result of urine, blood, semen, antiseptic agents, and infections such as cervicitis and vaginitis. The specificity of nitrazine paper has been reported as low as 16–70%.⁹ Ferning (crystallization of amniotic fluid seen on microscopic examination of dried amniotic fluid) has a reported sensitivity and specificity of 51% and 70%, respectively, in women not in labor and 98% and 88%, respectively, in laboring women.^{7,9}

Although many consider amniocentesis instillation of indigo carmine and vaginal tampon test to be the gold standard test, with a reported sensitivity and specificity of 100%, most feel the risk of this invasive procedure is not justified (trauma, bleeding, infection, preterm labor).⁷ In addition, a negative test may result if the membranes reseal after an initial leak, which has been reported in the literature to occur as high as 2–13% of the time.⁹ In recent

years researchers have set out to find an alternate, more objective and accurate way to detect ROM. These tests have been based primarily on the identification of biochemical markers present in the setting of ruptured membranes and absent in women with intact membranes. Multiple markers have been identified in the amniotic fluid, including α -fetoprotein (AFP), insulinlike growth factor binding protein-1 (IGFBP-1), prolactin, placental α -microglobulin-1 (PAMG-1), and fetal fibronectin, etc.^{7,9} To date, such immunoassay tests have been designed on the basis of monoclonal detection of proteins PAMG-1 (AmniSure, Cambridge, Massachusetts) and IGFBP-1 (Medix Biochemica, Kaunainen, Finland).^{10,11}

A new bedside immunoassay test (ROM Plus, Clinical Innovations, LLC, Murray, Utah) combines both monoclonal and polyclonal antibodies to detect 2 proteins found in amniotic fluid: placental protein 12 (PP12) and AFP. PP12, shown to be present in the amniotic fluid throughout pregnancy, was first purified from placenta and fetal membranes in 1980¹² and was therefore called *placental protein 12*. Eventually PP12, IGFBP-1 and PAMG-1 were all fully sequenced and reported to be essentially the same molecule.^{13–16}

AFP is synthesized by the fetal liver and yolk sac. During pregnancy the maternal serum and amniotic fluid AFP level increase with advancing gestational age and decrease during the third trimester.¹⁷ AFP has been shown to be a good marker for detecting premature rupture of the amniotic membranes in vaginal secretions, especially during the second trimester.^{18–25}

The unique monoclonal/polyclonal antibody approach makes this test very sensitive. This occurs because the polyclonal antibodies combine with multiple (8–12) amino acid epitopes contained in the 259 full-length PP12 protein chain, while the monoclonal tests combine with a single epitope site.

Currently, there is no study showing the performance of a combination monoclonal/polyclonal immunoassay test used to detect 2 proteins for ruptured membranes. The current study compares the accuracy of this new rapid, bedside immunoassay test with that of conventional clinical assessment for the diagnosis of ROM.

Materials and Methods

A multicenter, prospective, observational cohort study was performed involving healthy pregnant patients aged ≥ 18 years, between 15–42 weeks of

gestation, and presenting with signs or symptoms of ROM from July 2010–May 2011. Patients with known placenta previa and/or active vaginal bleeding were excluded from the study. The study was approved by each of 3 hospitals' Institutional Review Boards, and written consent was obtained from all participants for the collection and subsequent analysis of specimens and clinical data including the chart review.

All patients were evaluated for ROM beginning with a detailed history, a physical examination, and swab collection for the immunoassay test. The swab contained in the kit was used to collect cervicovaginal fluid without the use of a speculum prior to the conventional evaluation. The patient also underwent a sterile speculum examination without use of lubricant for the purpose of looking for conventional signs of ROM.

An initial diagnosis of ROM was made from the standard conventional evaluation from the sterile speculum examination of all patients using the following criteria: (1) if 2 of the following 3 clinical signs were present: pooling of fluid in the posterior fornix, microscopic evidence of ferning, and a positive nitrazine test, or (2) if amniotic fluid was seen leaking from the cervical os on speculum examination.¹

The monoclonal/polyclonal immunoassay test was performed according to the manufacturer's instructions by a clinician (nurse, midwife, or obstetrician) other than the one who performed the sterile speculum examination. Figure 1 is a photograph of the test kit device. A swab supplied by the manufacturer was placed approximately 2–3 inches into

the vagina for 15 seconds and cervicovaginal secretions were collected. Following collection the vaginal swab was then placed into a plastic vial and mixed in a buffer solution for 15 seconds and then applied directly to the test cassette (immunochromatographic lateral flow device). The test was interpreted after a minimum of 5 and a maximum of 20 minutes (using a timer integrated into the cassette) as positive for 2 lines (amniotic fluid [AF] and control line [C]), negative for 1 line (C line only), and invalid if no lines were visible. Any line visible to the naked eye was interpreted as a positive line. The threshold of detection for the new immunoassay test is 5 ng/mL for PP12 and 150 ng/mL for AFP. The provider who performed the sterile speculum examination was blinded to the results of the immunoassay test, and all patients were managed by ACOG-recommended gestational age-specific algorithms of treatment¹ without regard to the immunoassay test result. A questionnaire regarding the test results, the ease of use, and design of the product was completed for each patient by the clinician who interpreted the test. An initial decision as to the membrane status was made, and then after delivery a chart review of the entire clinical course of all patients—by a physician blinded to the results of the immunoassay test—was used for confirmation and final determination of membrane status. The longitudinal assessment of the patient's pregnancy (including initial examination, follow-up examinations, and subsequent clinical course) as determined by review of the medical records after delivery was used as the final clinical diagnosis to determine whether or not the patient had ROM at

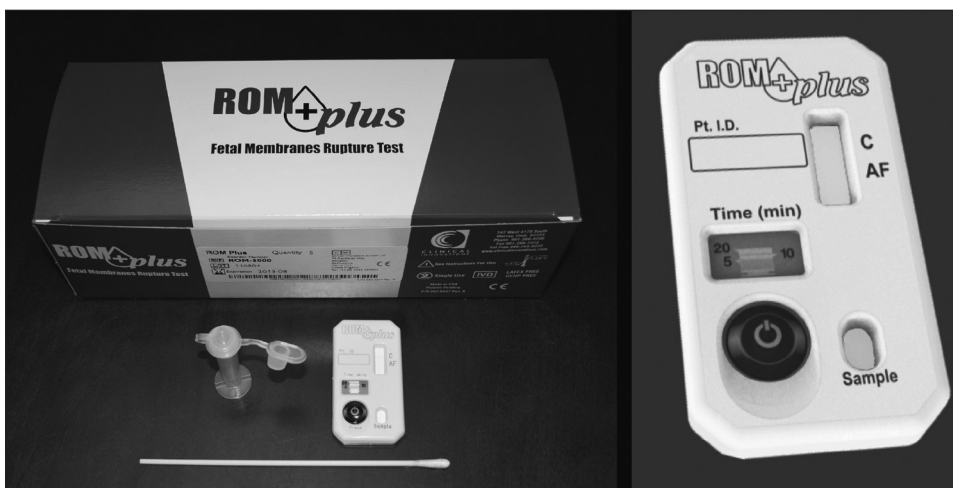

Figure 1 Photograph of the new Immunoassay Test Kit showing the sample window, lateral flow window with labels C (control line), AF (amniotic fluid line), and timer with activation button.

the initial visit. This methodology has been previously reported in the literature.^{5-7,26} The chart review was performed by a provider blinded to the results of the immunoassay test. The criteria used to determine membrane status included (1) results of the sterile speculum examination, (2) time from initial examination to delivery, (3) ultrasound assessment of amniotic fluid, (4) presence or absence of chorioamnionitis, (5) whether artificial ROM (AROM) was performed in labor, (6) delivery route, and (7) whether spontaneous ROM was to have occurred during labor.

Statistical Methods

Diagnostic accuracy was measured using the test characteristics: sensitivity, specificity, positive predictive value (PPV), and negative predictive value (NPV). These were reported with two-sided 95% confidence intervals (CIs). Sample size was determined using the precision method, where a sample size is selected to achieve a desired precision, or width, of the 95% CI. Having assumed both sensitivity and specificity to be 97%, a sample size of 90 would provide a 95% CI with a lower bound of 90%. To allow for approximately one-third of patients to be negative for ROM and two-thirds positive, a sample size of about $n=270$ patients would be needed to have a 95% CI lower bound above 90% for specificity in the patients negative for ROM.

Results

A total of 288 patients were enrolled in the study; 3 patients were not included in the final data analysis: 1 patient was < 18 years old, and 2 patients were lost to follow-up. Of those included in the analysis, 69% (198) were at term (≥ 37 weeks' gestational age), and 31% were preterm. The range was 15–42 weeks. A total of 162 (57%) were initially diagnosed with ruptured membranes using the conventional clinical evaluation and 196 (69%) using the new immunoassay test (Figure 2). Subsequent review of the medical records after delivery confirmed that 188 (66%) had ruptured membranes, whereas 97 (34%) had intact membranes. It should be noted that relying solely on leaking from the cervical os during sterile speculum examination for the diagnosis of ROM would have led to ~60% misdiagnosis.

There were 36 (13%) discrepant results between the conventional clinical evaluation and the immunoassay test. Using the final clinical diagnosis (conventional clinical evaluation plus chart review), 9 of the discrepancies were determined to be

false-positive immunoassay results, for a total false positive rate of 9% ($FP/TN + FP = 9/97$). One discrepancy was determined to be a false negative, for a rate of 0.5% ($FN/TP + FN = 1/188$).

Using the final clinical diagnosis, this new immunoassay test confirmed ROM at initial presentation with a sensitivity of 99% (187 of 188, 95% CI 0.97–1.00), specificity of 91% (88 of 97, 95% CI 0.83–0.95), PPV of 95% (187 of 196), and NPV of 99% (88 of 89). Comparing the conventional clinical evaluation (sterile speculum examination) alone to the final clinical diagnosis, the sterile speculum examination had a sensitivity of 85%, specificity of 98%, PPV of 99%, and NPV of 77%. Ferning alone showed a sensitivity of 99%, specificity of 72%, PPV of 80%, and NPV of 99% when compared to the final clinical diagnosis. Nitrazine alone showed a sensitivity of 93%, specificity of 83%, PPV of 90%, and NPV of 88% when compared to the final clinical diagnosis (Table I). As seen from Table I, the sensitivity of the immunoassay test is better than any of the individual standard components of the conventional clinical evaluation for ruptured membranes. The specificity of this new immunoassay test (91%) compares favorably with the conventional clinical evaluation (98%) and better than ferning or nitrazine alone. The PPV compares well with all methods and the NPV is equal to or better than all 3 approaches.

Table II shows the immunoassay test results (by gestational age) obtained in the clinical study as compared with the final clinical diagnosis results. Six of the 9 false positives were at term and only 3 of 9 were preterm. Data are presented as sensitivity and specificity with confidence intervals for all gestational age groups, term and preterm groups, < 24 weeks' gestational age, 24–34 weeks, and > 34 weeks' gestational age.

The clinical users who performed the multisite clinical study consisted of 28 OB Residents in training, 2 Family Practice Residents in training, 1 MFM Attending, 11 Midwives, and 6 Nurses. The overall percentages for the performance of different parts of the examination/testing were as follows: (1) sterile speculum examination: MFM Attending = 16%, Residents = 66%, Midwife/Nurses = 18%, (2) new immunoassay test collection: MFM Attending = 14%, Residents = 68%, Midwife/Nurses = 18%, and (3) new immunoassay test interpretation: MFM Attending = 4%, Residents = 72%, Midwife/Nurses = 24%. The new test design was rated excellent in 181 cases (64%) and good-to-satisfactory in 97 cases

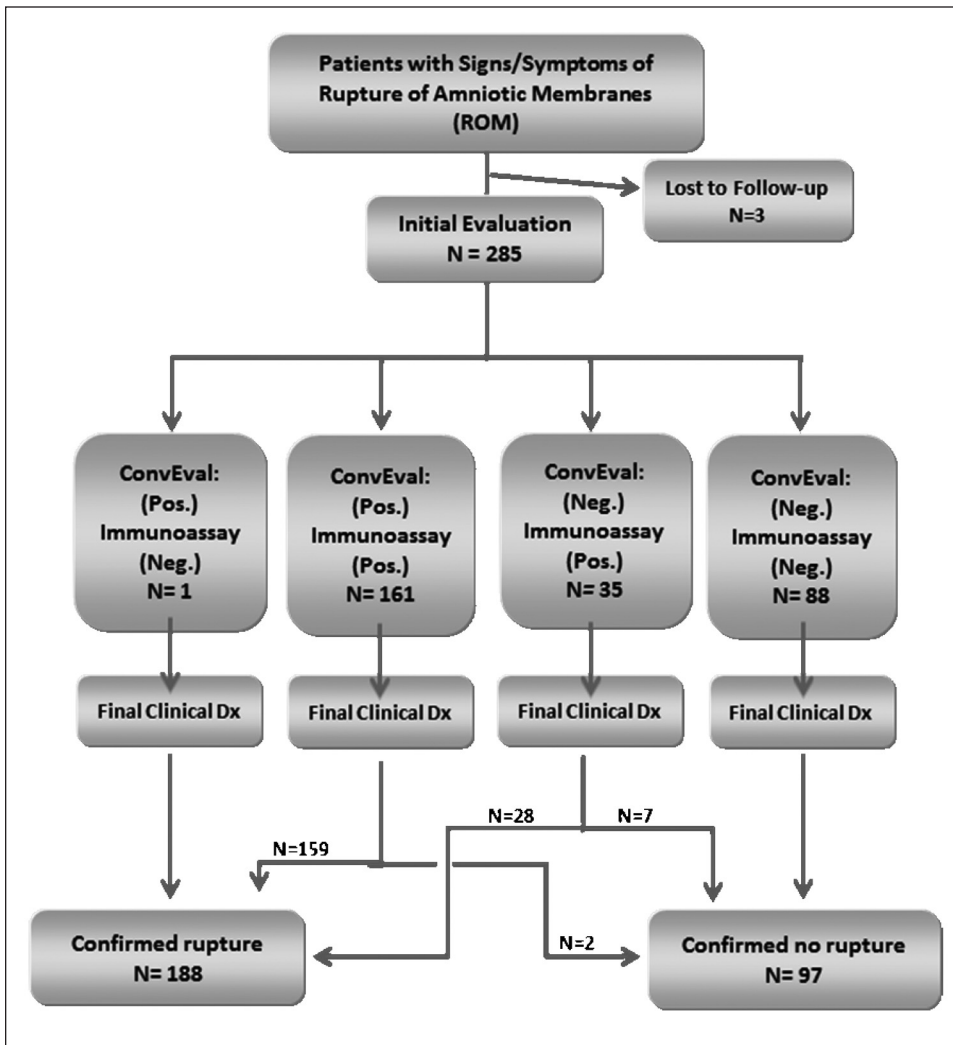


Figure 2 Flow diagram results for total patient population of the multicenter study. Conventional evaluation results are from standard speculum examination of pooling, ferning, nitrazine. ROM = rupture of amniotic membranes, Neg = negative result, Pos = positive result, Conventional evaluation = sterile speculum examination results, Final clinical Dx = evaluation of patient’s clinical course in diagnosing true rupture on initial examination.

Table 1 Comparison of Conventional Evaluation (Standard Speculum Examination of Pooling, Ferning, Nitrazine), Ferning Alone, Nitrazine Alone, and the New Immunoassay Test Results, Each Relative to Clinical Assessment (Reference Standard)

	Conventional evaluation vs. final clinical diagnosis	Immunoassay test vs. final clinical diagnosis	Ferning vs. final clinical diagnosis	Nitrazine vs. final clinical diagnosis
All gestational ages, total	285	285	285	285
True negative	95	88	96	85
True positive	160	187	150	170
False positive	2	9	38	18
False negative	28	1	1	12
Sensitivity	0.85	0.99	0.99	0.93
	CI 0.79–0.89	CI 0.97–1.00	CI 0.96–1.00	CI 0.89–0.96
Specificity	0.98	0.91	0.72	0.83
	CI 0.93–0.99	CI 0.83–0.95	CI 0.64–0.79	CI 0.74–0.89
PPV	0.99	0.95	0.80	0.90
	CI 0.96–1.00	CI 0.90–0.98	CI 0.73–0.85	CI 0.85–0.94
NPV	0.77	0.99	0.99	0.88
	CI 0.69–0.84	CI 0.94–1.00	CI 0.94–1.00	CI 0.80–0.93

Shown on the test characteristics with two-sided 95% confidence intervals.

Table II Sensitivity and Specificity for the Immunoassay Test at Various Gestational Age Groups

Gestational age (wks)	N	Sensitivity (95% confidence interval)	Specificity (95% confidence interval)
All	285	99.5 (97.0, 99.9)	90.7 (83.3, 95.0)
≥37	198	99.4 (96.4, 99.9)	86.0 (72.7, 93.4)
<37	87	100 (89.6, 100)	94.4 (84.9, 98.1)
>34	236	99.4 (96.7, 99.9)	88.5 (76.4, 93.8)
24–34	36	100 (83.2, 100)	100 (89.0, 100)
<24	13	100 (43.9, 100)	80 (49.0, 94.3)

(34%). Ease of use was rated excellent in 143 cases (50%) and good in 135 cases (47%). There were no complaints for difficulties in interpretation of the results, nor concerns for the safety or efficacy of the device.

Discussion

Given that preterm PROM is associated with significant perinatal mortality and morbidity, the development of an accurate test to confirm the diagnosis of ROM would be of great benefit. Furthermore, the development of a point-of-care test that is both accurate and easy to use by a wide array of clinicians (nurses, midwives, physicians, etc.) would be a true asset.

The accurate diagnosis of fetal membrane rupture remains a common clinical problem. The “clinical standard” for the diagnosis of ROM is subjective and relies on the ability of a clinician to visualize pooling of amniotic fluid in the posterior fornix of the vagina, document an alkaline vaginal pH, and identify ferning of the cervicovaginal secretions microscopically. Because each of these tests is subjective and susceptible to interference, individually they may lead to unacceptable false positive and false negative rates and are therefore not ideal reference standards. Because of the limitations of current testing methods, investigators have sought alternative markers. Although these markers are predictive for patients with intact membranes or unequivocal membrane rupture, they are often considered unnecessary due to cost, testing complexity, and low test sensitivities in cases of equivocal rupture. The absence of a noninvasive “gold standard” for the diagnosis of PROM has led to continued development of advanced biochemical markers. Despite improved diagnostic value in equivocal cases of suspected membrane rupture, biochemical markers may lack sufficient sensitivity

and specificity. In the common clinical situation where a healthcare provider encounters a patient with an equivocal diagnosis of ruptured membranes, diagnostic accuracy is the key to successful management and improved perinatal outcome. Nearly one quarter of all patients ultimately diagnosed with ROM do not present with overt clinical evidence of ruptured membranes.⁷

This clinical study demonstrates that a new combination monoclonal/polyclonal immunoassay is an accurate method for diagnosing ROM. In this group of patients spanning 3 labor and delivery units, this new, rapid, immunoassay test was an accurate and easily used method for diagnosing ROM in symptomatic women across a wide gestational age range, with an overall sensitivity of 99%, specificity of 91%, PPV of 95%, and NPV of 99%. Analysis also showed that the test’s sensitivity was superior to combined clinical testing (ferning, pooling, and nitrazine), and its specificity was superior to ferning or nitrazine testing alone.

Although we recognize the limitations of including a chart review of the clinical course along with the conventional examination as a final clinical diagnosis, this is generally how physicians ultimately determine the status of a patient’s membranes, and this methodology is supported by previous clinical studies.^{5-7,26} It is often true that a diagnosis cannot be made (with utmost certainty) until after the patient delivers, but in practice one often obtains information regarding the clinical course that, in retrospect, makes the diagnosis of the presence or absence of ROM more certain.

A false-positive test (defined as a positive immunoassay test in women who were subsequently found not to have ROM) was documented in 9 cases, for a total false-positive rate of 9%. Although the cause of these false-positive results is currently unknown to us, this rate is significantly less than the false-positive rate reported by Lee et al²⁶ associated with the immunoassay test identifying PAMG-1. Schuman²⁷ proposed that amniotic fluid can initially dissect between the amnion and the chorion prior to clinically obvious ROM, and immunoassays for amniotic proteins are more sensitive in detecting subclinical ROM with minute amounts of fluid leaking through microperforations in the membranes near term. Nuutila et al²⁸ concluded that phosphorylated isoforms of PP12 are present in cervical secretions of women with intact fetal membranes produced by decidual cells and reflect cervical ripeness in preparation for delivery. Further

studies are needed to verify this explanation and to determine the clinical significance of these observations. While this technically would result in a positive diagnosis of ROM before the membranes were actually ruptured, it would be clinically valuable because it would presage the event and hold the same clinical utility for patient management as if there had been overt ROM. These results and other recent immunoassay reports suggest that perhaps the value of immunoassay protein tests are to alert the physician of the presence of these proteins in the vaginal secretions but not that there necessarily exists gross rupture of the amniotic membranes.²⁶ This suggests the value of these tests lies in their use as an aid for evaluation of ROM and in conjunction with other clinical assessment before invasive therapy is instituted. In term patients a false positive has less significance than in preterm patients as the treatment will most likely not change significantly. We recognize that when this assay is used in preterm patients with equivocal clinical findings, a positive result should be evaluated in light of the clinical scenario before a decision is made to deliver, and we would consider amniocentesis a useful confirmatory procedure in these rare cases. A false negative result at <34 weeks can be very worrisome, as failure to treat can result in serious underestimation of the risk to the pregnancy, and resultant morbidity. The results of this study could be more significant with a greater number patients, especially at lower gestational ages, although confidence intervals at these ages are > 0.81.

In conclusion, this new immunoassay test proves to be a rapid, accurate, and easy to use point-of-care test for aiding in the diagnosis of ROM. The ROM Plus is a practical test to be performed by point-of-care clinicians including nurses, midwives, and physicians. Its performance in a multicentered, prospective study illustrates the superior sensitivity and specificity to ferning and nitrazine testing alone and suggests that it may be superior to immunoassay tests using monoclonal antibodies alone.

References

1. American College of Obstetricians and Gynecologists: ACOG Practice Bulletin No. 80: Premature rupture of membranes. Clinical management guidelines for obstetrician-gynecologists. *Obstet Gynecol* 2007;109:1007-1019
2. Naeye RL, Peters EC: Causes and consequences of premature rupture of fetal membranes. *Lancet* 1980;1:192-194
3. Naef RW 3rd, Allbert JR, Ross EL, et al: Premature rupture of membranes at 34 to 37 weeks' gestation: Aggressive versus conservative management. *Am J Obstet Gynecol* 1998; 178:126-130
4. Neerhof MG, Cravello C, Haney EL, et al: Timing of labor induction after premature rupture of membranes between 32 and 36 weeks' gestation. *Am J Obstet Gynecol* 1999;180:349-352
5. Cousins LM, Smok DP, Lovett SM, et al: AmniSure placental alpha microglobulin-1 rapid immunoassay versus standard diagnostic methods for detection of rupture of membranes. *Am J Perinatol* 2005;22:317-320
6. Lee SE, Park JS, Norwitz ER, et al: Measurement of placental alpha-microglobulin-1 in cervicovaginal discharge to diagnose rupture of membranes. *Obstet Gynecol* 2007;109:634-640
7. El-Messidi A, Cameron A: Diagnosis of premature rupture of membranes: Inspiration from the past and insights for the future. *J Obstet Gynaecol Can* 2010;32:561-569
8. Albayrak, M, Ozdemir I, Koc O, et al: Comparison of the diagnostic efficacy of the two rapid bedside immunoassays and combined clinical conventional diagnosis in prelabour rupture of membranes. *Eur J Obstet Gynecol Reprod Biol* 2011;158:179-182
9. Caughey A, Robinson J, Norwitz E: Contemporary diagnosis and management of preterm premature rupture of membranes. *Rev Obstet Gynecol* 2008;1:11-22
10. Konstantinov A, Foux B, Stepanov A, et al: Method for detecting free insulin-like growth-factor-binding protein 1 and a test device for detecting the ruptures of fetal membranes using the above method. USA Patent #5597700, April 28, 1994
11. Rutanen EM, Bohn H, Seppälä M: Radioimmunoassay of placental protein: Levels in amniotic fluid, cord blood and serum of healthy adults, pregnant women and patients with trophoblastic disease. *Am J Obstet Gynecol* 1982;144:460-463
12. Bohn H, Kraus W: Isolierung und charakterisierung eines neuen plazentaspezifischen proteins (PP12). *Arch Gynecol* 1980;229:279-291
13. Koistinen R, Kalkkinen N, Huhtala ML, et al: Placental protein 12 is a decidual protein that binds somatomedin and has an identical n-terminal amino acid sequence with somatomedin-binding protein from human amniotic fluid. *Endocrinology* 1986;118:1375-1378
14. Rutanen EM, Koistinen R, Wahlström T, et al: Synthesis of placental protein 12 by human decidua. *Endocrinology* 1985;116:1304-1309
15. Rutanen EM: Diagnostic method for detecting the rupture of fetal membranes. USA Patent #5554504, June 30, 1993
16. Fuks B, Notovskaya M, Nazimova S, et al: Antibodies to free IGFBP-1. USA Patent #5891722, April 6, 1999
17. Seppälä MM, Ruoslahti E: Alpha fetoprotein in amniotic fluid: An index of gestational age. *Am J Obstet Gynecol* 1972; 114:595-958
18. Weiss PA, Pürstner P, Lichtenegger W, et al: Alpha-fetoprotein content of amniotic fluid in normal and abnormal pregnancies. *Obstet Gynecol* 1978;51:582-585
19. Kishida T, Yamada H, Negishi H, et al: Diagnosis of premature rupture of the membranes in preterm patients, using an improved AFP kit: Comparison with ROM-check and/or nitrazine test. *Eur J Obstet Gynecol Reprod Biol* 1996;69:77-82

20. Shahin M, Raslan H: Comparative study of three amniotic fluid markers in premature rupture of membranes: Prolactin, beta subunit of human chorionic gonadotropin, and alpha-fetoprotein. *Gynecol Obstet Invest* 2007;63:195-199
21. Kishida T, Hirao A, Matsuura T, et al: Diagnosis of premature rupture of membranes with an improved alpha-fetoprotein monoclonal antibody kit. *Clin Chem* 1995;41:1500-1503
22. Rochelson BL, Richardson DA, Macri JN: Rapid assay: Possible application in the diagnosis of premature rupture of the membranes. *Obstet Gynecol* 1983;62:414-418
23. Rochelson BL, Rodke G, White R, et al: A rapid colorimetric AFP monoclonal antibody test for the diagnosis of preterm rupture of the membranes. *Obstet Gynecol* 1987;69:163-166
24. Mizejewski GJ: Levels of alpha-fetoprotein during pregnancy and early infancy in normal and disease states. *Obstet Gynecol Surv* 2003;58:804-826
25. Yamada H, Kishida T, Negishi H, et al: Comparison of an improved AFP kit with the intra-amniotic PSP dye-injection method in equivocal cases of preterm premature rupture of the fetal membranes. *J Obstet Gynaecol Res* 1997;23:307-311
26. Lee SM, Lee J, Seong HS, et al: The clinical significance of a positive Amnisure test in women with term labor with intact membranes. *J Matern Fetal Neonatal Med* 2009;22:305-310
27. Schuman W: Double sac with secondary rupture of the bag of waters during labour: A clinical entity and its explanation from examination of the membranes. *Am J Obstet Gynecol* 1951;62:633-638
28. Nuutila M, Hilesmaa V, Karkkainen T, et al: Phosphorylated isoforms of insulin-like growth factor binding protein-1 in the cervix as a predictor of cervical ripeness. *Obstet Gynecol* 1999;94:243-249

The results described in the attached document
have not been approved or cleared by the FDA